DOI 10.1515/pjvs-2015-0103

Original article

Can liquorice extract and herbal solution prevent colonic mucosa damage caused by robenacoxib in dogs?

M. Szweda[1], J. Szarek[1], M. Lew[2], A. Szarek-Bęska[3], D. Gulda[4]

[1] Department of Pathophysiology, Forensic Veterinary Medicine and Administration, Faculty of Veterinary of the University of Warmia and Mazury in Olsztyn, Oczapowskiego St. 13, 10-719 Olsztyn, Poland
[2] Department of Surgery and Radiology with Clinic, Faculty of Veterinary Medicine of the University of Warmia and Mazury in Olsztyn, Oczapowskiego St. 14, 10-719 Olsztyn, Poland
[3] Veterinary Practice „Pulsar", Wiecherta St. 27A, 10-691 Olsztyn, Poland
[4] Department of Sheep, Goat and Fur Bearing Animal Breeding, University of Science and Technology, Kordeckiego 20F, 85-225 Bydgoszcz, Poland

Abstract

Non-steroidal anti-inflammatory drugs (NSAIDs) are commonly used in animals, especially in dogs, to manage pain due to inflammatory disease. This study investigated whether plant drugs can prevent mucosal injury induced by robenacoxib. We used fifteen healthy beagle dogs (7 male and 8 female) aged 4 months, weighing 4.2-5.1 kg at the beginning of the study. Endoscopy and biopsy of the colon were performed before and on the 21 day treatment with robenacoxib (1), robenacoxib, herbal solution with liquorice extract (2), placebo – an empty capsule (3). There were 5 animals in each group. The greatest microscopic damage in the colon was observed in animals which received robenacoxib. Plant drug administration reduced the severity of lesions in the colon when administered with robenacoxib (ARI = – 0.15). Conclusion: concurrent administration of liquorice extract and plant solution with robenacoxib was associated with significant decreased severity of the robenacoxib-induced colonic mucosal lesions.

Key words: robenacoxib, plant drugs, colonoscopy, prevention, dog

Introduction

Coxibs cause gastrointestinal damage in dogs. They have proven analgesic and anti-inflammatory effects, mostly for musculoskeletal disorders (Lascelles et al. 2007). The mode of action of NSAIDs lies in the inhibition of the enzyme cyclooxygenase (COX) (Sakamoto et al. 2006, Lascelles et al. 2007). Prostaglandins, produced by the gastrointestinal mucosa, appear to mediate mucosal defense (Almansori et al. 2005). While effective at relieving inflammation and pain, coxibs are associated with the potential risk of adverse intestinal effects (Almansori et al. 2005). Long-term NSAID therapy can generate erosions, submucosal hemorrhages, rare ulceration or perforation (Deneuche et al. 2004, Jankowski et al. 2015). It is appropriate, therefore, to search for new strategies, including the co-administration of mucoprotective plant extracts (Blumenthal et al. 2000, Huo et al. 2011).

The healing properties of liquorice extract on the mucosa may result from stimulation of mucus syn-

Correspondence to: M. Szweda, e-mail: magda_szweda@tlen.pl

thesis (Blumenthal et al. 2000). Liquorice preparations seem to be successful in treating spasmodic pain in chronic gastritis. The mucoprotective effect of liquorice has been examined previously in dogs (Morris et al. 1974, Langmead and Lampton 2001). We used liquorice root powder in capsules at a dose of 50 mg per day (Lukrecja; Herbapol Kraków, Poland).
In our study we also used a herbal solution consisting of saponariae root, thyme, icelandic lichen and hyssop root. Icelandic lichen exhibits antibacterial and anti-inflammatory activity, and inhibits gastric acid secretion. In veterinary practice Icelandic lichen is often used to treat erosions, gastric hyperacidity, and mucosal inflammation (Langmead and Lampton 2001, Frondoza et al. 2004). The herb hyssop can significantly reduce the number of intestinal bacteria and binding of bacterial toxins. Hyssop reduces gastromucosal inflammation and smooth muscle tension (Poppenga 2001). In animals, the herb thyme is used to prevent peptic ulcers by increasing the secretion of mucus. Moreover, thyme exhibits antibacterial activity (Smart et al. 1986). Saponariae root has been used successfully in human medicine to protect the intestinal mucosa (Langmead and Lampton 2001). We used the tested herbal solution described above in dogs at an oral dose of 0.1 ml/kg daily (Pectosol; Herbapol Pruszków, Poland).

The present study was designed to investigate the effects of a combination treatment of a selective COX-2 inhibitor – robenacoxib – with herbal preparations with potential mucosal – protective action. Our aim was to determine the extent to which liquorice extract with herbal solution exhibits protective effects when co administered with robenacoxib.

Materials and Methods

The study was approved by the Animal Research Local Ethics Committee of the University of Warmia and Mazury, Olsztyn, Poland.

Animals and experimental design

Fifteen beagle dogs (7 male and 8 female) aged 4 months, weighing 4.2-5.1 kg were used in the present study. Before the study complete blood count and serum biochemical analyses was performed to confirm that the dogs were healthy. The dogs were placed in three boxes, with five in each box. No mortality occurred during the study and, apart from diarrhea and occasional blood in the feces, no abnormalities were recorded. The study comprised 21 days of treatment. All treatments were administered daily by the same investigator, who performed a health examination each day for evidence of vomiting, diarrhea, inappetance, or abdominal pain.

The dogs were randomly assigned to one of three treatment groups ($n=5$ in each group). Group 1: 2 mg/kg robenacoxib *per os*, daily (Onsior; Novartis, United Kingdom), group 2: 2 mg/kg robenacoxib and 50 mg/dog liquorice extract, and 0.1 ml/kg herbal solution *per os*, daily. The dogs in control group 3 received an empty capsule orally.

Colonoscopy was done before and after three weeks to take a mucosal biopsy. During endoscopic investigation material for histopathological examination was collected. Specimens were fixed in 10% buffered formalin, then saturated with intermediate solutions, and finally embedded in paraffin blocks. Sections were stained with hematoxylin and eosin (Jacobs et al. 1990, Kleinschmidt et al. 2006). Histopathological evaluation of the colonic mucosa was performed using the NIS-Elements BR 2.30 programme (Nikon, Japan) under a Nikon Eclipse 80i optical microscope equipped with a Nikon PS – Fi1 digital camera (Eclipse 80i; Nikon, Japan) in the field of view (20 x 10). Microscopic lesions were assessed using the author's scale: no deviation from normal tissue (designated as 0 – no obvious changes compared to normal tissue); very minor lesions (designated as 1 – changes to 30% of the tissue); moderate lesions (designated as 2 – changes to 31-60% of the tissue). According to this scale four types of lesions were evaluated, among them are infiltration of the lamina propria with lymphoid cells, connective tissue proliferation, increased diameter of glands and hyperemia.

Statistical analysis

Analyses of histopathological lesions in the colonic mucosa allowing comparison between the groups were carried out using the chi-squared test, Cochran's Q test and by calculating the z scores. The Statistica 9.1 programme was used.

Results

Cochran's Q test yielded statistically significant differences among dogs in the groups ($p<0.001$). The highest number of differences, 80%, were noted in animal group 1, whereas dogs from group 2 varied just 20% from the placebo group.

The chi-squared test revealed significant differences among animals in the groups for infiltration of lymphoid cells. For this variable, the lowest results were reported in animals from group 1 (variable in

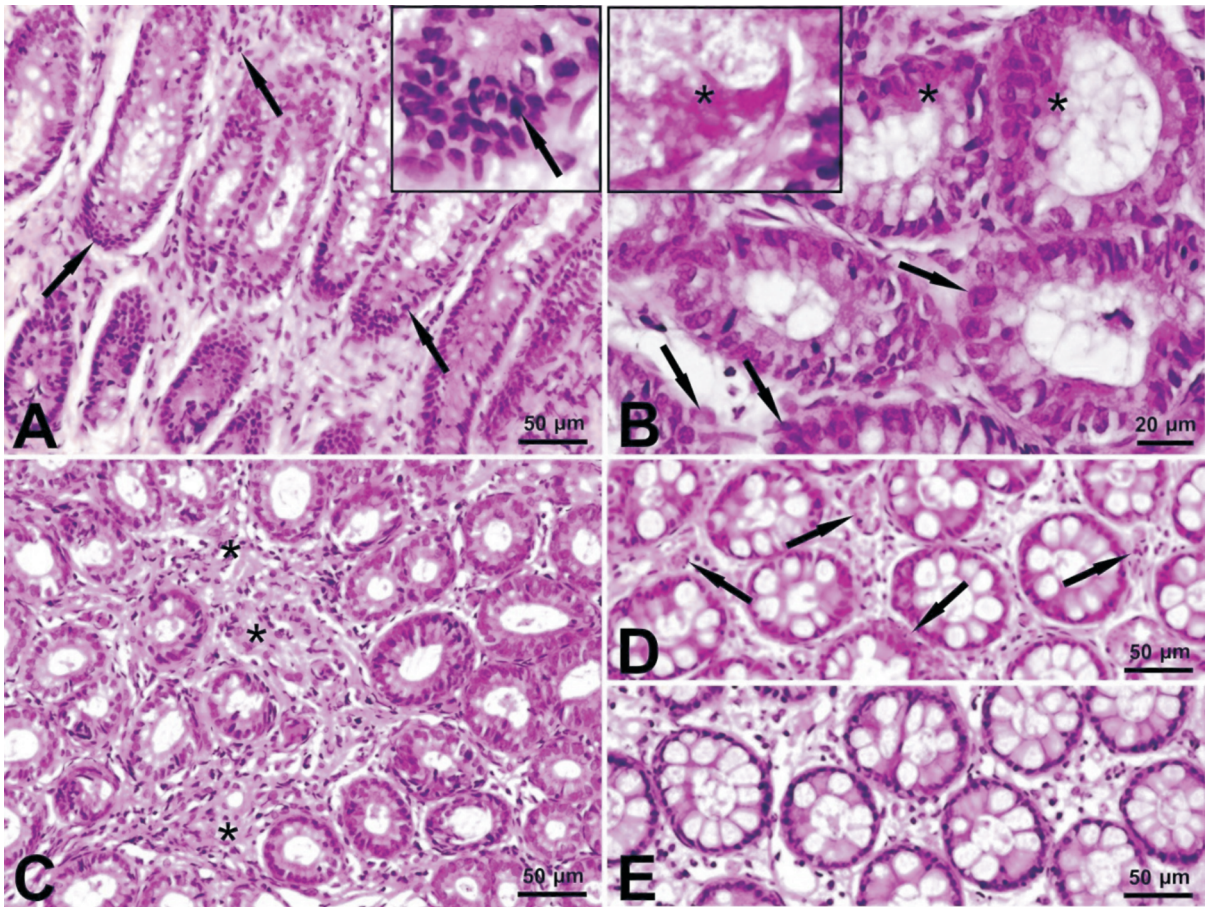

Fig. 1. Morphological pattern of the colonic mucosa on day 21 of the experiment: A. Moderate focal infiltration of lymphoid cells including crypts (arrows), in the right corner double magnification – group 2; B. Swollen glands filled with a large amount of mucus (asterisks) and sloughed epithelial cells (arrows), in the left corner double magnification – group 1; C. Connective tissue laying a thick band between the crypts (asterisks) – group 1; D. The blood vessels in the mucous membrane (arrows); E. Colonic mucosa without lesions – group 3. HE staining, magnification as on the scale in micrometers.

Table 1. The scores distribution (in points of own scale / in percentages) of the lesions in the colonic mucosa in dogs of the day 21 of the experiment.

Group	Infiltration of lymphoid cells		
	without	minor	moderate
1	1 / 20	4 / 80	0 / 0
2	4 /80	1 / 20	0 /0
3	5 / 100	0 / 0	0 / 0
Increase in the diameter of glands			
1	1 / 20	3 / 60	1 / 20
2	4 / 80	1 / 20	0 / 0
3	5 / 100	0 / 0	0 / 0
Proliferation of the connective tissue			
1	2 / 40	3 / 60	0 / 0
2	4 / 80	1 / 20	0 / 0
3	4 / 80	1 / 20	0 / 0
Hyperemia			
1	0 / 0	4 / 80	1 / 20
2	3 / 60	2 / 40	0 / 0
3	5 / 100	0 / 0	0 / 0

4 dogs), in which the z scores were significant and achieved the result 2.22. Minor infiltration with lymphoid cells was found in just one individual from group 2 (Fig. 1). These results most closely resembled the findings in the control group, where this variable was not detected (Table 1).

The chi-squared test also revealed differences among the animals between groups for the increase in the diameter of glands in the colonic mucosa (p=0.00364). The majority of animals in which the this lesion was found were in the groups administered robenacoxib; it was detected in 4 dogs (3 minor changes and 1 moderate). In all cases, the lesions were mild (Fig. 1B). This type of change was observed in biopsy specimens from one dog administered coxib and plant remedies. This change was not observed in biopsies in dogs from the placebo group. The z score for this finding was statistically significant and achieved the result 2.09 (Table 1).

For the changes defined as proliferation of the connective tissue the chi-squared test revealed a lack

of statistically significant differences among the groups (p=0.10319). Minor proliferation of the connective tissue was found in colonic biopsy specimens from three dogs administered coxib (Fig. 1C), one dog administered coxib with plant remedies, and one which received an empty gelatin capsule (Table 1).

For hyperemia, we found that most of this variable was in animals which received coxib for 21 days (the highest z score was for group 1 – 2.49). In group 1 hyperemia was detected in all specimens (Fig. 1D). In group 2, this type of lesion was found in 2 of the individuals, whereas in the placebo group it was not detected (Fig. 1E). In each case of this variable the lesions were mild (Table 1).

According to the percentage distribution of hyperemia in dogs that were simultaneously administered robenacoxib and plant products, the plant remedies decreased the risk of hyperemia in the colon.

The risk of histopathological lesions in the colonic mucosa increased most rapidly in animals from group 1 (absolute risk increase [ARI] = – 0.75). Whereas the best result was recorded in dogs which received the plant remedies together with coxib (group 3; ARI = – 0.20). Absolute risk increase in the control group – 0.15. In all cases, the confidence interval included the integer 1.

Discussion

This study, under experimental conditions, was the first to explore the effects of herbal remedies on colonic mucosa in dogs; the effects of co administration of coxib and herbal remedies have not been reported previously. Our study also focused on colon side effects in dogs treated with NSAIDS for 21 days, which is a chronic treatment (Jones et al. 1992). We noticed that most studies in veterinary medicine on side effects associated with administration of NSAIDS have been limited to the stomach, and, rarely, the duodenum. Recent studies in humans have indicated that coxibs may also increase the risk of mucosa damage to the lower section of the gastrointestinal tract (Bjarnason et al. 1993, Luna et al. 2007, Fujimori et al. 2008, 2009). The results of our study, under laboratory conditions, provide further confirmation of the above observations.

None of the dogs in the present study developed clinically observed side effects. This information cannot be transferred to a clinical setting, in which patients are in pain and have other concurrent diseases. In such circumstances lesions may be exacerbated and result in clinical worsening. Recently, new reports have revealed that coxibs can induce colonic damage in dogs (Bernardi et al. 1994, Jackson 2000, King et al. 2009). Our histopathological studies indicated that robenacoxib can damage the mucosa of the distal gastrointestinal tract. In a previous study in dogs aged 6 months, the administration of much higher doses of robenacoxib than those used in our study was not associated with histopathological lesions in the colonic mucosa (King et al. 2010, Gruet et al. 2011, 2013).

Based on our and some other researchers findings there is obviously need for medicinal compounds with protective actions on the gastrointestinal tract of dogs. (Chen and Zhang 1990). In recent years have been few studies about herbal medicines successfully used in the treatment of ulcerative colitis in people (Bernardi et al. 1994). There have been also couple studies of the effects of herbal remedies in dogs, most of this studies have indicated that the herbal solution can be used in veterinary medicine for the treatment of intestinal disorders, with promising results (Blumenthal et al. 2000, Poppenga 2001, Viegi et al. 2003). In our study, we found that only dogs receiving tested herbal solution and liquorice extract coo administered with robenacoxib showed no signs of irritation the colonic mucosa. It is worth noting that liquorice has been used in humans in the treatment of large bowel ulcerations and gastric ulcers (Bernardi et al. 1994, Viegi et al. 2003). This results are similar to ours in field of large intestine.

In order to precisely examine the impact of the products that we tested on the colonic mucosa of dogs, we performed first endoscopy, than additionally microscopic examinations taken samples. The most frequent changes were observed in coxib group, as opposed to group 2, which the least differed from the placebo group. Comparisons results among the groups with accordance to the severity and prevalence of different types of lesions showed that the most severe infiltration of lymphoid cells into the colonic mucosa was observed in animals from group 1. For comparison this type of changes was detected in only one dog received coxib and the plant remedies (group 2).

What is important also increases in gland diameters were observed most often in dogs received robenacoxib in monotherapy. The authors want to pay attention that increases in gland diameters was detected just in one dog administered robenacoxib and the plant remedies.

Proliferation of connective tissue in the colonic mucosa was observed in 3 dogs that received coxib alone, and just in one dogs from group 2 and 3.

In biopsy specimens collected from all dogs received for 21 days coxib authors found colonic mucosa hyperemia. Our results clearly suggest that use of the two tested remedies containing herbs may, when coo administered with robenacoxib, significantly decrease

the risk of coxib-induced damage in the colonic mucosa of young healthy dogs.

Conclusions

In our innovative study, we were able to prove that robenacoxib induced lesions in the colonic mucosa of healthy beagle dogs when administered for three weeks. However, when tested coxib was administered together with liquorice extract and herbal solution, definitive smaller damage was observed, what was confirmed by histopathological examination.

The most severe microscopic lesions were associated with coxib administration. Moreover this tested herbal combination was not associated with extensive histopathological lesions in biopsy specimens. The tested plant remedies appeared to significantly reduce the severity of coxib-induced damage to the colonic mucosa.

At this point we would like to highlight that mentioned results do not apply to all dogs. There are a need to additional studies to measure the pharmacokinetics of tested herbal solution and liquorice extract in accordance with the distribution and elimination phases. This could confirm the suitability of proposed by authors protocol for chronic use in veterinary settings.

Acknowledgement

The authors are indebted to Ms. Krystyna Dublan (Department of Pathophysiology, Forensic Veterinary Medicine and Administration, University of Warmia and Mazury in Olsztyn, Poland), MSc and Mr. A. Penkowski, MSc (Department of Animal Anatomy, University of Warmia and Mazury in Olsztyn, Poland) for their excellent technical assistance.

References

Almansori M, Kovithavongs T, Qarni MU (**2005**) Cyclooxygenase-2 inhibitor-associated minimal change disease. Clin Nephrol 63: 381-384.

Bernardi M, D'Intino PE, Trevisani F, Cantelli-Forti G, Raggi MA, Turchetto E, Gasbarrini G (**1994**) Effects of prolonged ingestion of graded doses of licorice by healthy volunteers. Life Sci 55: 863-872.

Bjarnason I, Hayllar J, MacPherson AJ, Russell AS (**1993**) Side effects of nonsteroidal anti-inflammatory drugs on the small and large intestine in humans. Scand J Gastroenterol 104: 1832-1847.

Blumenthal M, Goldberg A, Brinckmann J, Foster S (**2000**) Licorice root. In: Herbal medicine – Expanded Commission E Monographs. American Botanical Council, Austin, USA, pp 233-239.

Chen Q, Zhang H (**1990**) Clinical study on 118 cases of ulcerative colitis treated by integration of traditional Chinese and Western medicine. JTCM 19: 163-165.

Deneuche AJ, Dufayet C, Goby L, Fayolle P, Desbois C (**2004**) Analgesic comparison of meloxicam or ketoprofen for orthopedic surgery in dogs. Vet Surg 33: 650--660.

Frondoza CG, Sohrabi A, Polotsky A, Phan PV, Hungerford DS, Lindmark L (**2004**) An in vitro screening assay for inhibitors of proinflammatory mediators in herbal extracts using human synoviocyte cultures. In Vitro Cell Dev Biol Anim 40: 95-101.

Fujimori S, Seo T, Gudis K, Ehara A, Kobayashi T, Mitsui K, Yonezawa M, Tanaka S, Tatsuguchi A, Sakamoto C (**2009**) Prevention of nonsteroidal anti-inflammatory drug-induced small-intestinal injury by prostaglandin: a pilot randomized controlled trial evaluated by capsule endoscopy. Gastrointest Endosc 69: 1339-1346.

Gruet P, Seewald W, King JN (**2013**) Robenacoxib versus meloxicam for the management of pain and inflammation associated with soft tissue surgery in dogs: a randomized, non-inferiority clinical trial. BMC Vet Res 9: 92.

Gruet P, Seewald W, King JN (**2011**) Evaluation of subcutaneous and oral administration of robenacoxib and meloxicam for the treatment of acute pain and inflammation associated with orthopedic surgery in dogs. Am J Vet Res 72: 184-193.

Huo HZ, Wang B, Liang YK, Bao YY, Gu Y (**2011**) Hepatoprotective and antioxidant effects of licorice extract against CCl4-induced oxidative damage in rats. Int J Mol Sci 12: 6529-6543.

Jackson LM, Wu KC, Mahida YR, Jenkins D, Hawkey CJ (**2000**) Cyclooxygenase (COX) 1 and 2 in normal, inflamed, and ulcerated human gastric mucosa. Gut 47: 762-770.

Jacobs G, Collins-Kelly L, Lappin M, Tyler D (**1990**) Lymphocytic-plasmacytic enteritis in 24 dogs. J Vet Intern Med 4: 45-53.

Jankowski M, Spużak J, Kubiak K, Glińska-Suchocka K, Biernat M, Kiełbowicz Z (**2015**) Risk factors of gastric ulcers in dogs. Pak Vet J 35: 93-97.

Jones RD, Baynes RE, Nimitz CT (**1992**) Nonsteroidal anti-inflammatory drug toxicosis in dogs and cats: 240 cases (1989-1990). J Am Vet Med Assoc 201: 475-477.

King JN, Dawson J, Esser RE, Fujimoto R, Kimble EF, Maniara W, Marshall PJ, O'Byrne L, Quadros E, Toutain PL, Lees P (**2009**) Preclinical pharmacology of robenacoxib: a novel selective inhibitor of cyclooxygenase-2. J Vet Pharmacol Ther 32: 1-17.

King JN, Rudaz C, Borer L, Jung M, Seewald W, Lees P (**2010**) In vitro and ex vivo inhibition of canine cyclooxygenase isoforms by robenacoxib: a comparative study. Res Vet Sci 88: 497-506.

Kleinschmidt S, Meneses F, Nolte I, Hewicker-Trautwein M (**2006**) Retrospective study on the diagnostic value of full-thickness biopsies from the stomach and intestines of dogs with chronic gastrointestinal disease symptoms. Vet Pathol 43: 1000-1003.

Langmead L, Rampton DS (**2001**) Review article: herbal treatment in gastrointestinal and liver disease – benefits and dangers. Aliment Pharmacol Ther 15: 1239-1252.

Lascelles BD, Hansen BD, Roe S, DePuy V, Thomson A, Pierce CC, Smith ES, Rowinski E (**2007**) Evaluation of

client-specific outcome measures and activity monitoring to measure pain relief in cats with osteoarthritis. J Vet Intern Med 21: 410-416.

Luna SP, Bastlio AC, Steagall PV, Machado LP, Moutinho FQ, Takahira RK, Brand4o CV (**2007**) Evaluation of adverse effects of long-term oral administration of carprofen, etodolac, flunixin meglumine, ketoprofen and meloxicam in dogs. Am J Vet Res 68: 258-264.

Morris TJ, Calcraft BJ, Rhodes J, Hole D, Morton MS (**1974**) Effect of deglycyrrhizinised liquorice compound on the gastric mucosal barrier of the dog. Digestion 11: 355-363.

Poppenga RH (**2001**) Herbal medicine: potential for intoxication and interactions with conventional drugs. Clin Tech Small Anim Pract 17: 6-18.

Sakamoto C, Sugano K, Ota S, Sakaki N, Takahashi S, Yoshida Y, Tsukui T, Osawa H, Sakurai Y, Yoshino J, Mizokami Y, Mine T, Arakawa T, Kuwayama H, Saigenji K, Yakabi K, Chiba T, Shimosegawa T, Sheehan JE, Perez-Gutthann S, Yamaguchi T, Kaufman DW, Sato T, Kubota K, Terano A (**2006**) Case-control study on the association of upper gastrointestinal bleeding and nonsteroidal anti-inflammatory drugs in Japan. Eur J Clin Pharmacol 62: 765-772.

Smart HL, Mayberry JF, Atkinson M (**1986**) Alternative medicine consultations and remedies in patients with the irritable bowel syndrome. Gut 27: 826-828.

Viegi L, Pieroni A, Guarrera PM, Vangelisti R (**2003**) A review of plants used in folk veterinary medicine in Italy as basis for a databank. J Ethnopharmacol 89: 221-244.